

Background

Tracheoesophageal fistulas (TEFs) are most commonly encountered and discussed in the setting of a congenital abnormality. Less frequently encountered and discussed in anesthesia literature are acquired TEFs and their management.

Reported common causes of acquired TEFs include malignancy / radiation, infection, trauma, and prolonged mechanical ventilation. Epidemiologic data regarding this topic is insufficient to estimate the occurrence of acquired TEFs.

TEF definitive repair is always surgical. Depending on the size and location of the fistula, the management of the airway requires thoughtful consideration and planning.

This case report presents the anesthetic management of a patient with a large tracheoesophageal fistula at a large tertiary care center.

Case Description

A 51yo male with a history of polytrauma complicated by prolonged intubation and subsequent tracheostomy was found to have large tracheoesophageal (TE) fistula and severe tracheomalacia. This occurred in the setting of multiple self-extubations and tracheostomy reinsertions by ENT while in ICU. He had previously undergone repair of the known anterior defect which extended from the 1st to 5th tracheal rings. Despite the repair, the patient continued to have persistent air leakage, desaturations, and displacement of his tracheostomy, which can be seen on CT imaging (Figure 1).

The patient was evaluated for repair by multiple surgical teams (ENT, trauma surgery, and CT surgery). During workup, the patient's airway remained unstable due to multiple episodes of self extubation. ENT advanced the tracheostomy distal to the fistula with a flexible bronchoscope as a temporizing measure.

Given the large defect, significant air leak, and instability of the surgical airway, it was decided by trauma surgery and anesthesia teams that the patient be taken to the OR urgently for placement of VV- ECMO and additional attempt at surgical repair. Upon arrival to OR he had a notable air leak of ~100mL and active bubbling around tracheostomy site. Following establishment of ECMO, the patient was able to undergo complex reconstruction of the TE fistula by the trauma surgery team with the unstable airway. The anterior repair to the esophagus and extent of tracheal defect is pictured (Figure 3).

The defect was found to be approximately 5-6cm, located 8-9cm above the carina, and extending from the first to fifth tracheal rings with large anterior and posterior defects. The patient subsequently remained on ECMO for 6 days following procedure and has not required additional surgical interventions at this time.

Discussion

Acquired TEF is a rare occurrence and definitive repair is always surgical. A TEF will require complex repair and presents a unique challenge to both surgical and anesthesia teams.

When deciding on possible strategies to manage this airway, the options required consideration of timing, resources, and individual patient factors. Early consideration of alternative airway management and coordination between providers and resources can facilitate a successful outcome.

When airway challenges arise or are anticipated, early consideration of ECMO is a lifesaving skill.

References

Bibas BJ, Cardoso PFG, Minamoto H, Pêgo-Fernandes PM. Surgery for intrathoracic tracheoesophageal and bronchoesophageal fistula. *Ann Transl Med.* 2018 Jun;6(11):210. doi: 10.21037/atm.2018.05.25. PMID: 30023373; PMCID: PMC6035972.

Raman Diddee, MB BS FRCA, Ian H Shaw, BSc PhD MB BChir FRCA, Acquired tracheo-oesophageal fistula in adults, *Continuing Education in Anaesthesia Critical Care & Pain*, Volume 6, Issue 3, June 2006, Pages 105–108, <https://doi.org/10.1093/bjaceaccp/mkl019>

Robins, Berkle MD; Das, Asish K. MD Anesthetic Management of Acquired Tracheoesophageal Fistula: A Brief Report, *Anesthesia & Analgesia*: October 2001 - Volume 93 - Issue 4 - p 903-905 doi: 10.1097/00000539-200110000-00020

Santosham R. Management of Acquired Benign Tracheoesophageal Fistulae. *Thorac Surg Clin.* 2018 Aug;28(3):385-392. doi: 10.1016/j.thorsurg.2018.05.004. PMID: 30054076.

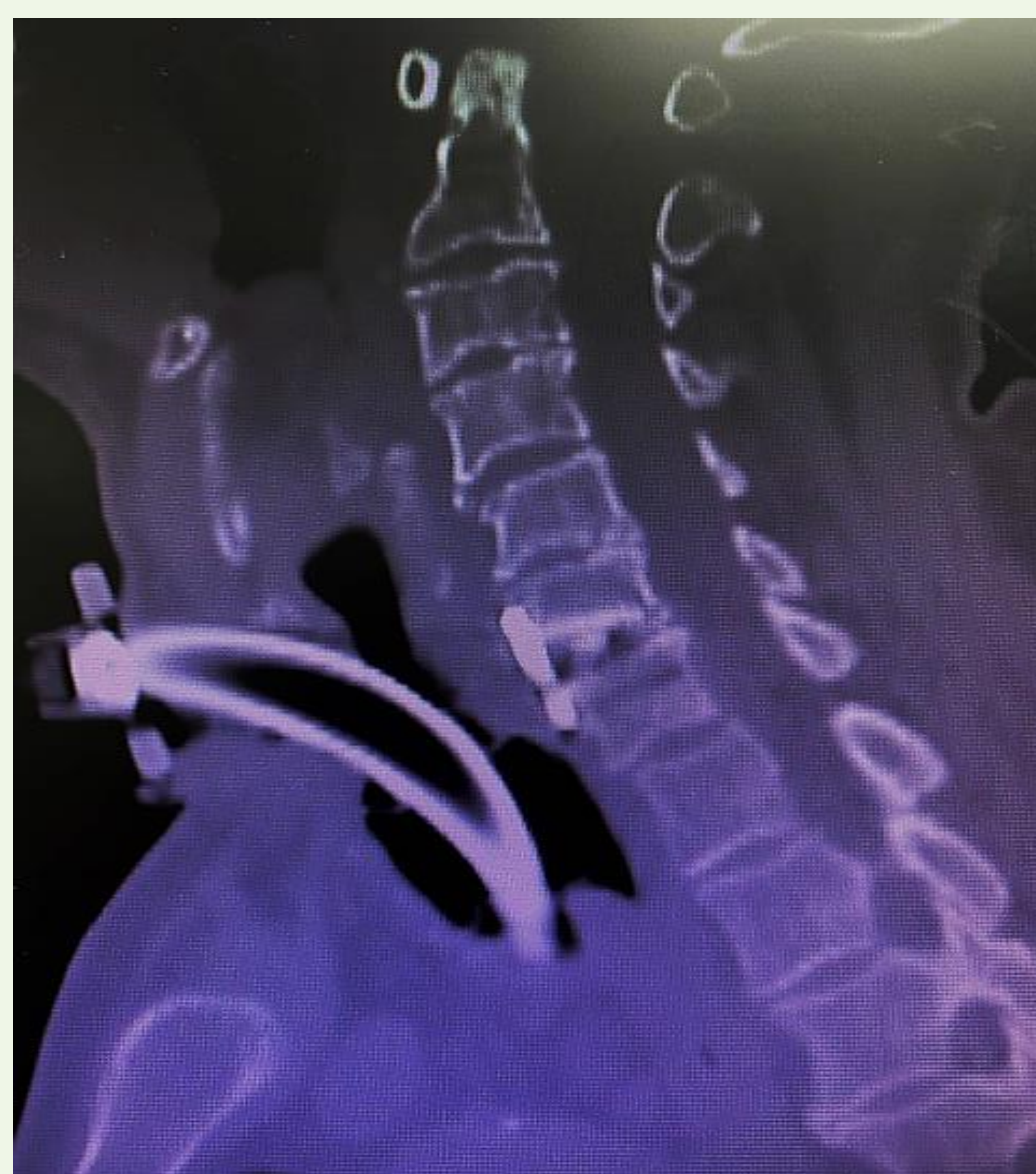

Figure 1

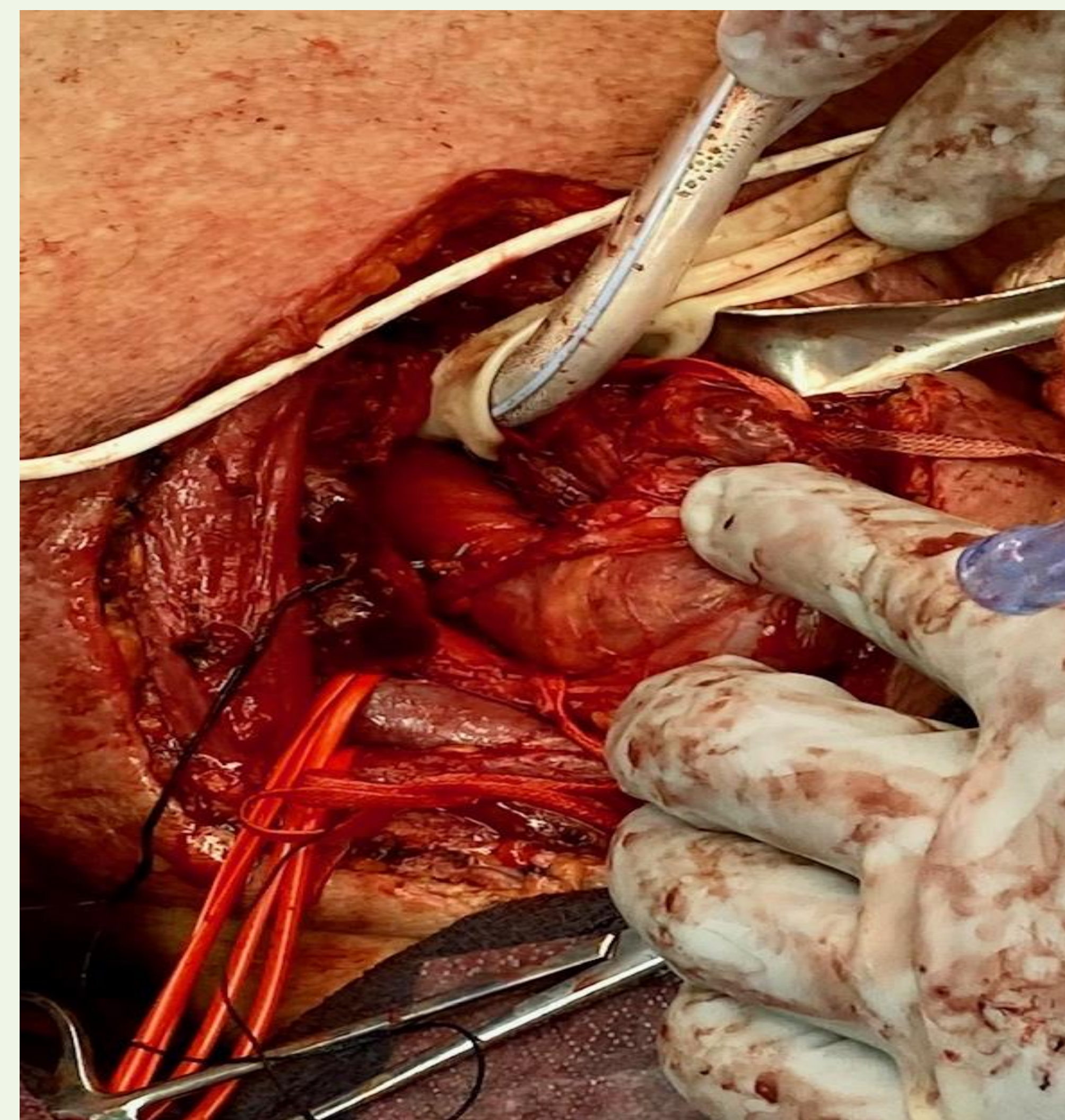


Figure 2